



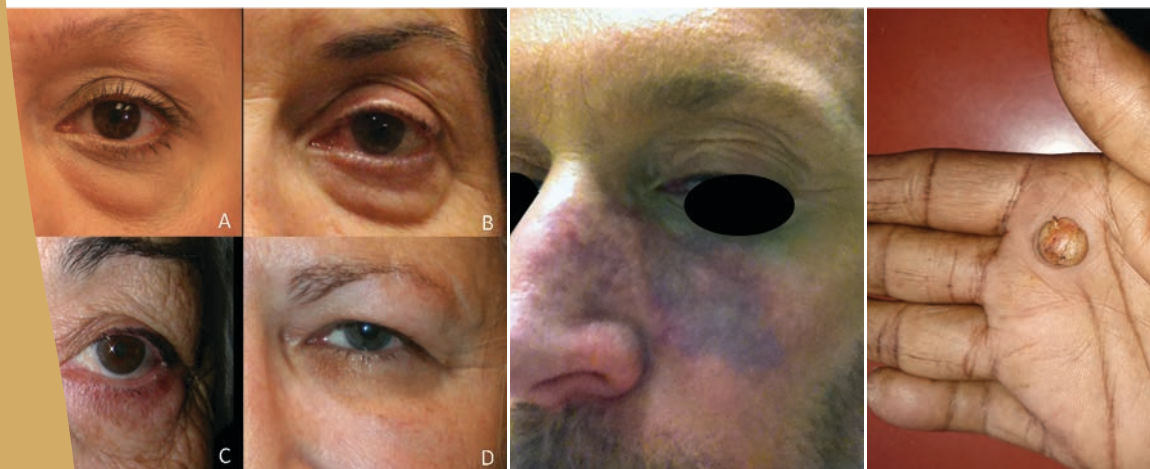
ISSN 0974-2077

Volume 9 | Issue 2 | June 2016

Journal of Cutaneous and Aesthetic Surgery

Official Journal of Association of Cutaneous Surgeons of India

JCAS



Online full text at
www.jcasonline.com

Highlights of the Issue

- Symposium on Periocular rejuvenation
- Hills and Valleys: Understanding the Under-Eye
- Infraorbital Dark Circles
- Periorbital Injectables: Understanding and Avoiding Complications
- Blepharoplasty Basics for the Dermatologist
- Eyelash Transplantation for the Treatment of Vitiligo

PubMed

Medknow

 Wolters Kluwer

An Unusual Eyelid Mass of Cysticercosis: A Twist in the Tale

Poonam J Rai¹, Akshay Gopinathan Nair^{1,2,3,4}, Mihir G Trivedi¹, Nayana A Potdar¹, Indumati Gopinathan⁴,
Chhaya A Shinde¹

¹Department of Ophthalmology, Lokmanya Tilak Municipal Medical College and General Hospital, ²Department of Ophthalmic Plastic Surgery, Ocular Oncology and Facial Aesthetics, Advanced Eye Hospital and Institute, Navi Mumbai, ³Aditya Jyot Eye Hospital, Mumbai, ⁴Clinico-Pathological Laboratories, Mumbai, Maharashtra, India

Address for correspondence: Dr. Akshay Gopinathan Nair, Department of Ophthalmic Plastic Surgery, Ocular Oncology and Facial Aesthetics, Advanced Eye Hospital and Institute, Sanpada, Navi Mumbai - 400 705, Mumbai, Maharashtra, India. E-mail: akshaygn@gmail.com

ABSTRACT

Cysticercosis is a parasitic infestation caused by the larval form of the tapeworm, *Taenia solium* (*T. solium*). The common sites for cysticercosis include the brain, eyes, and skeletal muscle. Ocular or adnexal involvement is commonly seen with the commonest ophthalmic site being subretinal space and the vitreous cavity. However, only a handful of cases of eyelid cysticercosis have been reported in the past. We report a rare and unusual case of isolated eyelid cysticercosis in a middle-aged woman masquerading as an asymptomatic slowly growing subcutaneous painless mass in the left eyelid which was presumed to be a benign skin mass, a cyst of appendageal origin such as an epidermoid cyst. This case highlights the ubiquitous nature of cysticercosis in tropical countries and the need for a high degree of suspicion while surgically treating subcutaneous masses. We would additionally emphasize the need to rule out neurocysticercosis in such cases.

KEYWORDS: Cysticercosis, epidermoid cyst, eye, eyelid, eyelid mass, neurocysticercosis

INTRODUCTION

Cysticercosis is a parasitic tissue infestation caused by larval cysts of the tapeworm *Taenia solium* (*T. solium*). The most common sites that are affected are the central nervous system, striated muscles, eyes, and subcutaneous tissue. In the eye, sites of infestation are 68% in the posterior segment, namely subretinal and intravitreal in location. The other ocular and adnexal sites include the anterior segment, the conjunctiva, and the orbit.^[1] Only a few cases of an eyelid cysticercosis have been documented in medical literature, among which, the frequency of the lower eyelid being involved is noted to be less.^[2-4] In this communication, we report a lower lid mass that was clinically appearing to be an epidermoid cyst due to its appearance and nature, but was histopathologically diagnosed as cysticercosis.

CASE REPORT

A 55-year-old female presented with swelling on the left lower eyelid. She was apparently asymptomatic a year ago when she noticed a small swelling near the left lower eyelid which had progressed to the present state. She sought cosmetic correction of the small mass, as she felt it appeared unsightly. On examination, the mass was painless, spherical, nontender, cystic, and appeared subcutaneous in location and measured 12 mm in diameter [Figure 1a]. Her ophthalmic evaluation was otherwise normal. She had primarily sought an opinion for excision of the mass for cosmetic reasons that were performed under local anesthesia. The cystic mass was excised

This is an open access article distributed under the terms of the Creative Commons Attribution-NonCommercial-ShareAlike 3.0 License, which allows others to remix, tweak, and build upon the work non-commercially, as long as the author is credited and the new creations are licensed under the identical terms.

For reprints contact: reprints@medknow.com

How to cite this article: Rai PJ, Nair AG, Trivedi MG, Potdar NA, Gopinathan I, Shinde CA. An unusual eyelid mass of cysticercosis: A twist in the tale. J Cutan Aesthet Surg 2016;9:126-8.

Access this article online

Quick Response Code:



Website:
www.jcasonline.com

DOI:
10.4103/0974-2077.184044

en masse and sent for histopathological examination. While located under the dermis, the mass was found to be separate from the eyelid tarsus and in close relation with the fibers of *orbicularis oculi*. The wound was sutured with interrupted 6-0 Vicryl sutures in layers: The first layer being *orbicularis oculi* followed by subcuticular sutures of the skin to avoid a scar. On gross examination the mass was a pea-sized greyish white cyst. Microscopic examination was consistent with a diagnosis of cysticercosis: the larva could be visualized within a cyst that showed three discrete layers: An outer cuticular layer, a middle cellular layer, and an inner fibrillar layer that could be seen in a typical racemose pattern [Figure 2]. A magnetic resonance imaging (MRI) of the brain and orbit showed no abnormality. Postoperatively, on the advice of an infectious disease specialist, who found no systemic involvement on the basis of examination and serology, the patient received a course of oral albendazole 400 mg for 5 days. At 1 year follow-up visit, no local or systemic recurrence was seen; the patient remained asymptomatic and the wound had healed well, except for minimal pigmentation with no trace of a scar [Figure 1b].

DISCUSSION

In the case of cysticercosis due to *T. solium*, the incubation period can vary, and infected people may remain asymptomatic for years. In some endemic regions (particularly in Asia), infected people may develop visible or palpable subcutaneous nodules. Gupta *et al.* have reported the use of ultrasonography to diagnose subcutaneous cysticercosis that showed characteristic low reflective cysts and high reflective scolices inside.^[4] Fine-needle aspiration cytology may additionally be an effective mode of diagnosis of subcutaneous cysticercosis.^[5] The clinical relevance of such subcutaneous lesions itself may be less, however, they may forebode the presence of cysticercosis of the central nervous system.^[5] Computed tomography (CT) imaging and MRI can confirm the diagnosis and

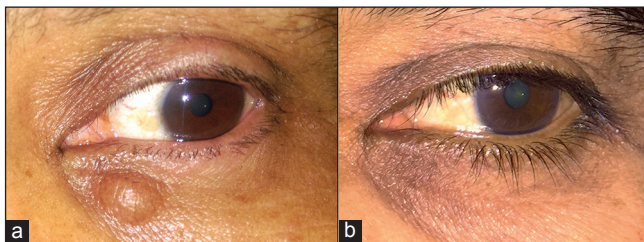


Figure 1: (a) An external photograph showing a lower eyelid mass. The mass is spherical in shape, nontranslucent, painless, and appears to be subcutaneous in location (b) An external photograph showing a lower eyelid, 1 year after surgery. A faintly visible scar with pigmentation is seen

additionally help to rule out neurocysticercosis.^[6] This is of further relevance because medical treatment of cysticercosis before screening for central nervous system involvement may cause a paradoxical reaction that may impair the outcome of cysticercosis during the treatment with antihelminthic drugs.^[7] It has been reported that tissue diagnosis is not essential for initiating treatment and in addition diagnosis of cysticercosis is based mainly on orbital imaging because of its highly specific appearance.^[8] However, in our case, the unusual location, misleading history, and atypical appearance precluded us from considering cysticercosis as a possible diagnosis. In their series, which is one of the largest compilations of cases of orbital and adnexal cysticercosis, Rath *et al.* reported only one case of eyelid cysticercosis, which was of the upper lid. While reviewing the literature, they have reported that the eyelid is the least common site affected in the eye.^[9] Common differential diagnoses for a longstanding cystic eyelid mass include dermoid cyst, sebaceous cyst, epidermoid cyst, neurofibroma, and a lipoma.^[10]

From the treatment perspective, surgical removal is the gold standard for subconjunctival and eyelid cysticercosis. Medical therapy is the recommended treatment for the extraocular muscle form and orbital cysticercosis.^[8]

CONCLUSION

We present a rare case of an isolated eyelid cysticercosis, masquerading as a benign eyelid mass, perhaps an epidermoid cyst, which may be a presenting signs of severe disease in an endemic area. Such patients should be evaluated thoroughly for underlying systemic

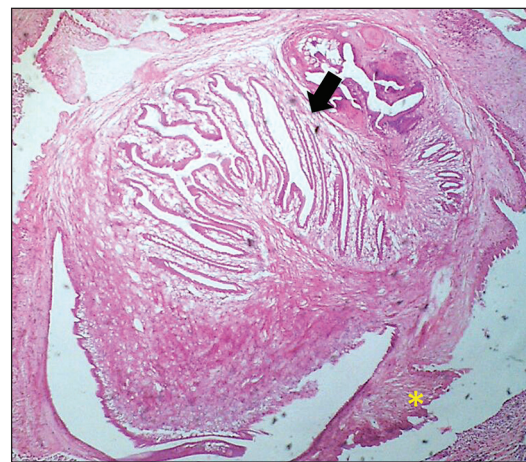


Figure 2: Photomicrograph (Hematoxylin and Eosin stained; 40×) showing the cysticercosis. Observe the outer wall of the cyst (black arrow) and the inner layers that are thrown in folds: A typical racemose pattern. The asterisk indicates striated muscle fibers seen below the lesion

disease. While a simple excision may suffice for cosmetic correction in such cases, isolated eyelid cysticercosis are uncommon and require a high degree of clinical suspicion and accurate histopathological evidence to diagnose.

Declaration of patient consent

The authors certify that they have obtained all appropriate patient consent forms. In the form the patient(s) has/have given his/her/their consent for his/her/their images and other clinical information to be reported in the journal. The patients understand that their names and initials will not be published and due efforts will be made to conceal their identity, but anonymity cannot be guaranteed.

Financial support and sponsorship

Nil.

Conflicts of interest

There are no conflicts of interest.

REFERENCES

1. Kaliaperumal S, Rao VA, Parija SC. Cysticercosis of the eye in South India - a case series. *Indian J Med Microbiol* 2005;23:227-30.
2. Chan EW, Looi A. Cysticercosis of the levator palpebrae superioris. *Ann Acad Med Singapore* 2010;39:938-2.
3. Nainiwal SK, Titiyal JS, Sen S. Intra-tarsal cysticercosis of the lower lid. *Orbit* 2002;21:223-5.
4. Gupta S, Jain VK, Sen J, Gupta S, Arora B. Subcutaneous cysticercosis involving the eyelid: Sonographic diagnosis. *J Dermatol* 2000;27:35-9.
5. Gill M, Dua S, Gill P, Gupta V, Gupta S, Sen R. Cytomorphological spectrum of subcutaneous and intramuscular cysticercosis: A study of 22 cases. *J Cytol* 2010;27:123-6.
6. Garcia HH, Nash TE, Del Brutto OH. Clinical symptoms, diagnosis, and treatment of neurocysticercosis. *Lancet Neurol* 2014;13:1202-15.
7. Epelboin L, Klement E, Chemali N, Danis M, Bricaire E, Caumes E. Neurocysticercosis complicating the treatment of cutaneous cysticercosis in a traveller. *Bull Soc Pathol Exot* 2004;97:250-2.
8. Pushker N, Bajaj MS, Betharia SM. Orbital and adnexal cysticercosis. *Clin Experiment Ophthalmol* 2002;30:322-33.
9. Rath S, Honavar SG, Naik M, Anand R, Agarwal B, Krishnaiah S, *et al.* Orbital cysticercosis: Clinical manifestations, diagnosis, management, and outcome. *Ophthalmology* 2010;117:600-5.
10. Amissah-Arthur KN, Mudhar HS, Sandramouli S. A longstanding cystic swelling of the upper eyelid. *Br J Ophthalmol* 2013;97:1352, 1361-2.